

Measurement of Optic Nerve and Optic Nerve Sheath Diameter in MRI Brain

Sharma Paudel, Sweta Joshi, Durga Pandey, Prakash Kayastha

Author(s) affiliation

Department of Radiodiagnosis,
Maharajgunj Medical Campus,
Tribhuvan University Teaching
Hospital, Institute of Medicine,
Maharajgunj, Kathmandu, Nepal

Corresponding author

Sweta Joshi, BScMIT, MScMIT
swetajoshi95@gmail.com

ABSTRACT

Introduction

Many diseases affect the size of the optic nerve and optic nerve sheath, measurement of which is important for the diagnosis and treatment of different pathologies of the brain and orbit. This study aimed to measure the diameter of the optic nerve and optic nerve sheath in MRI brain examinations. We also studied their variation according to age, gender, and laterality.

Methods

This cross-sectional, quantitative study was performed in the Radiology Department of Tribhuvan University Teaching Hospital (TUTH). The diameter of the optic nerve and optic nerve sheath were measured in the T2 weighted Dixon Turbo Spin Echo axial images. The diameter was measured at the level of 3mm and 8mm behind the eye globe. The study was completed over a period of 3 months (August 2023 to October 2023).

Results

The mean diameters of the optic nerve were 2.187 ± 0.35 mm/ 2.14 ± 0.35 mm at 3 mm behind the eye globe and 2.056 ± 0.334 mm/ 2.11 ± 0.35 mm at 8 mm behind the globe for the right/left sides respectively. The optic nerve sheath of the right/left sides measured 4.50 ± 0.60 mm/ 4.46 ± 0.56 mm at 3 mm behind the eye globe and 4.16 ± 0.50 mm/ 4.14 ± 0.47 mm at 8mm behind the eyeball.

Conclusion

The measurements for the diameter of the optic nerve and optic nerve sheath complex were similar in both the right and left eyes. There was no significant difference in optic nerve and optic nerve sheath diameters with the age and gender of the participants.

Keywords

MRI, optic nerve, optic nerve sheath

Submitted

Oct 31, 2023

Accepted

Nov 25, 2023

INTRODUCTION

Optic nerve (ON) is the second cranial nerve which is responsible for transmitting visual information from the eyes to the brain.¹ The Optic nerve sheath (ONS) is the outer meningeal covering of the optic nerve; consisting of the dura mater, arachnoid mater and pia mater.²

Various pathologies affect the diameter of the optic nerve (OND) and optic nerve sheath (ONSD) therefore it is important to know their normal reference values for a specific population. Due to the superior soft tissue contrast of magnetic resonance imaging (MRI) compared to computed tomography (CT), it can differentiate optic nerve from optic nerve sheath and allow us to measure them separately thus providing more accurate measurement compared to other modalities.³ This could be useful because different diseases may affect different parts of the optic nerve sheath complex; some affect the optic nerve and others may affect the optic nerve sheath.⁴ Fat saturation sequences in MRI suppress the fat component, which makes it easier to differentiate the optic nerve and the nerve sheath and hence allowing to measure them separately and correctly.

The purpose of this study was to measure the mean diameter of ON and ONS. To correlate variation of ON and ONS diameter with age, to determine significant differences in ON and ONS diameter in males and females, and to compare the diameter of ON and ONS in right and left eyes.

METHODS

This was a quantitative, cross-sectional study conducted in the Radiology Department of Tribhuvan University Teaching Hospital (TUTH) from August 2023 to October 2023. A total of 100 MRI brain

Table 1. Parameters of T2 weighted TSE Dixon axial sequence

Parameters	Values
TR	3540 ms
TE	81 ms
Slice thickness	3 mm
Flip angle	150
Distance factor	10 %
Matrix	512X512
Averages	2

scans, meeting the inclusion criteria, were included in the study using the purposive non-probability sampling method.

Ethical approval was obtained from the Institutional Review Committee of Institute of Medicine before data collection. Data was collected after obtaining verbal and written informed consent from the patients.

The inclusion criteria consisted of patients referred for MRI Brain scans between the age group of 15 to 80 years to the Radiology Department of TUTH. Exclusion criteria involved patients with a known history of related disorders that might affect the diameters of the optic nerve or optic nerve sheath such as increased intracranial pressure, optic neuritis, endocrine disorders, and patients with any kind of general contraindication for MRI examinations including implants, pacemakers or aneurysm clips.

All MR images were acquired on the Magnetom Amira Siemens 1.5 T MRI scanner. T2 weighted Turbo Spin Echo (TSE) Dixon axial images with a slice thickness of 3mm and distance factor of 10%, were used for measuring the optic nerve and optic

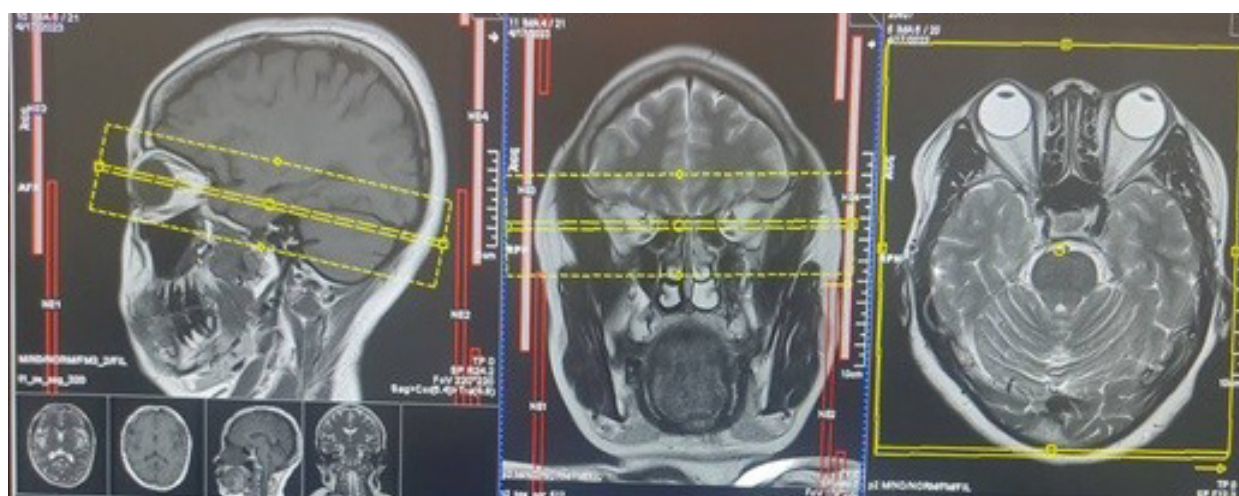


Figure 1. Planning of T2 weighted TSE Dixon axial sequence. The single yellow dotted lines denote the scan coverage superiorly to inferiorly. The double-dotted yellow line denotes the central slice. The yellow solid box indicates planning in the axial images to ensure adequate coverage in the anteroposterior and lateral sides.

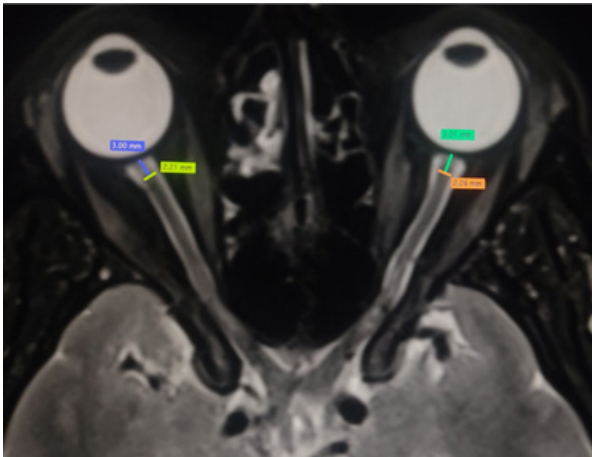


Figure 2. Measurement of optic nerve diameter (OND) at 3mm behind the eye globe in both eyes

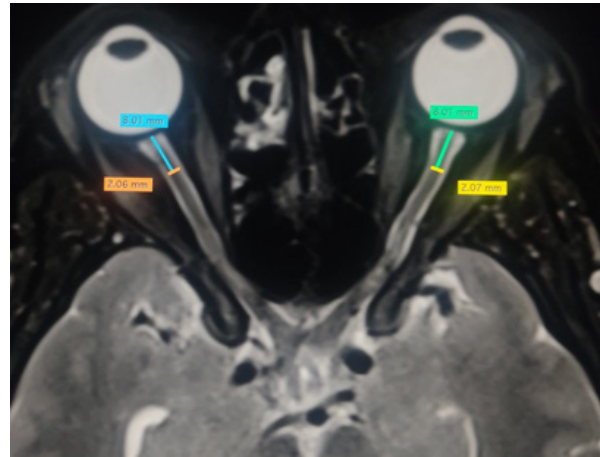


Figure 3. Measurement of optic nerve diameter (OND) at 8mm behind the eye globe in both eyes

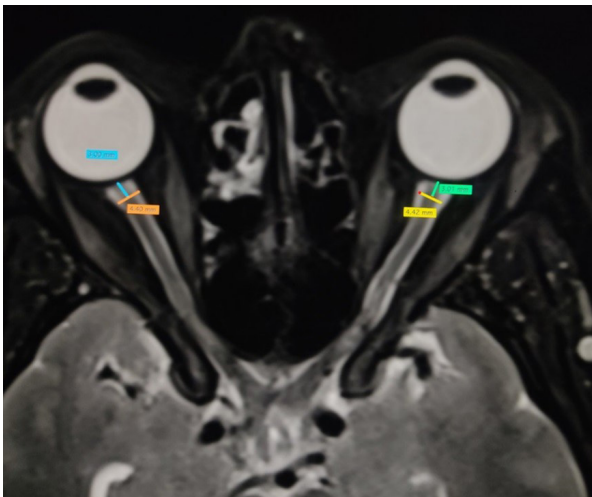


Figure 4. Measurement of optic nerve sheath diameter (ONSD) at 3mm behind the eye globe in both eyes

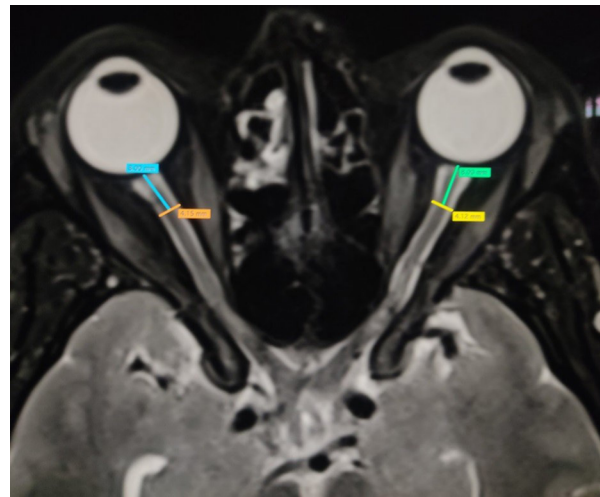


Figure 5. Measurement of optic nerve sheath diameter (ONSD) at 8mm behind the eye globe in both eyes

nerve sheath diameter (Figure 1). The TR selected was 3450ms and TE selected was 81ms; a matrix size of 512X512, a Field Of View (FOV) of 190mm, and 2 averages were selected (Table 1).

An informed written consent was obtained from the patient before the scan. Patients were thoroughly screened before the MRI examination. Patients were positioned in the supine position with their heads inside the head coil. The laser was centered over the glabella.

The measurements were carried out in two different parts of both the optic nerve and optic nerve sheath i.e. 3mm and 8mm behind the eye globe. A straight line was drawn behind the eye globe to locate 3mm and 8mm then, another line perpendicular to the first line was drawn and measurements were taken (Figures 2, 3, 4, and 5).

The obtained data was analyzed using SPSS version 26. Pearson correlation coefficient was used to

determine the relation between OND/ONSD with age of the patient. The difference in OND/ONSD between males and females was tested with the help of an independent samples t-test. Variation of OND/ONSD in the left/right eyes were tested with a paired t-test.

RESULTS

A total of 100 MRI scans were included in this study. Among them, there were 45 female patients and 55 male patients.

OND and ONSD

The mean optic nerve diameter (OND) of the right eye at 3mm behind the eye globe was 2.19 ± 0.35 mm and 8mm behind the eye globe was 2.06 ± 0.33 mm. Likewise, OND of the left eye was 2.14 ± 0.35 mm and 2.11 ± 0.35 mm at 3mm and 8mm behind the eye globe respectively.

Table 2. The OND and ONSD at 3mm and 8mm behind the eye globe for bilateral eyes (N=100)

Diameter and location	Mean \pm SD (mm)	Minimum (mm)	Maximum (mm)
Right OND at 3mm	2.19 \pm 0.35	1.44	2.84
Right OND at 8mm	2.06 \pm 0.33	1.28	2.90
Left OND at 3mm	2.14 \pm 0.35	1.21	2.99
Left OND at 8mm	2.11 \pm 0.35	1.27	2.81
Right ONSD at 3mm	4.50 \pm 0.60	3.08	5.82
Right ONSD at 8mm	4.16 \pm 0.50	3.05	5.35
Left ONSD at 3 mm	4.46 \pm 0.56	2.18	5.90
Left ONSD at 8mm	4.14 \pm 0.47	2.22	4.96

The mean optic nerve sheath diameter (ONSD) of the right eye at 3mm behind the eye globe was 4.50 \pm 0.60mm and 8mm behind the eye globe was 4.16 \pm 0.50mm. Likewise, ONSD of the left eye at was 4.46 \pm 0.56mm and 4.14 \pm 0.47mm at 3mm and 8mm behind the eye globe respectively (Table 2).

OND and ONSD of left and right sides

There was no statistically significant difference in the diameter of ON and ONS between right and left eyes at 3 mm and 8mm behind the eye globe using the paired sample t-test ($p > 0.05$). (Table 3).

Table 3. Comparison of the OND/ONSD between the right and left eyes

Diameter and location	t-value	p-value
OND at 3mm	1.096	0.28
OND at 8mm	-1.211	0.23
ONSD at 3mm	0.480	0.63
ONSD at 8mm	0.482	0.63

OND and ONSD with age

There was no significant correlation between age and bilateral optic nerve diameter, as well as age and bilateral optic nerve sheath diameter at both 3mm and 8mm behind the eyeball using the Pearson correlation coefficient (r ranging from 0.001 to 0.18) ($p > 0.05$) (Table 4).

OND and ONSD with gender

There was no significant difference in the diameter

of the bilateral optic nerve as well as optic nerve sheath between males and females at 3mm and 8mm behind the eye globe using an independent sample t-test. ($p > 0.05$) (Table 5).

DISCUSSION

Obtaining the reference normal diameters of the optic nerve and optic nerve sheath could be helpful in the differential diagnosis of various cranial and orbital pathologies by including or excluding various diseases.

Vaiman et.al in a study concluded that the diameter of optic nerve sheath had maximum variation at 3 mm and minimum variation at 8 mm behind the eye globe.⁵ Referencing a number of studies, we too measured the diameters of the optic nerve and optic nerve sheath at these two points viz. 3mm and 8mm behind the eye globe.^{4,5} In our study, however we did not find such differences in the ONSD at the two different positions.

Gadaikeri et.al in a study concluded that the multipoint Dixon technique offered better image quality and uniform fat suppression at a much shorter imaging time compared with STIR and spectral pre-saturation techniques.⁶ Referencing this study, we used Dixon as a fat suppression technique for our study which allowed better visualization of optic nerve and optic nerve sheath.

In our study, the OND ranged from 1.21 mm to 2.99 mm whereas the ONSD ranged from 2.18 mm to 5.9 mm. These findings were similar to those obtained by a previous study.⁴ ONSD measurements were

Table 4. Pearson's correlation coefficients between age with OND/OSND

Diameter and location	Right		Left	
	r- value	p- value	r- value	p- value
OND at 3mm and age	0.045	0.68	0.021	0.85
OND at 8mm and age	0.043	0.70	0.011	0.92
ONSD at 3mm and age	0.181	0.10	0.082	0.46
ONSD at 8mm and age	0.068	0.54	0.001	0.99

Table 5. Comparison of OND/ONSD between males and females

OND/ONSD	Gender	Mean (mm)	SD	t-value	p-value
OND Rt 3mm	Female	2.21	0.33	0.48	0.63
	Male	2.17	0.36		
OND Rt 8mm	Female	2.05	0.31	-0.22	0.82
	Male	2.06	0.36		
OND Lt 3mm	Female	2.15	0.36	0.01	0.98
	Male	2.15	0.36		
OND Lt 8mm	Female	2.11	0.32	-0.11	0.91
	Male	2.11	0.38		
ONSD Rt 3mm	Female	4.49	0.59	-0.08	0.93
	Male	4.51	0.62		
ONSD Rt 8mm	Female	4.07	0.50	-1.73	0.09
	Male	4.26	0.49		
ONSD Lt 3mm	Female	4.47	0.61	0.03	0.98
	Male	4.47	0.53		
ONSD Lt 8mm	Female	4.13	0.52	-0.11	0.91
	Male	4.15	0.42		

similar to those obtained by Kim et al. in MRI and KC et al. in Ultrasound.^{7,8} Other studies have shown a larger ONSD compared to our study.⁹

We did not find any significant correlation between optic nerve sheath diameter with the age of the participants. The brain shrinks with increasing age; there are changes in morphology as well as changes at the molecular level.¹⁰ However, we did not find any significant correlation between the optic nerve and nerve sheath diameters with increasing age. These findings were similar to the study by Kim et.al in MRI and Avci et al. in Ultrasonography.^{8,11}

We also found no significant difference in the OND and ONSD between males and females similar to previous studies.^{5,8} Another study found OND variation with gender for the right eye at 3 mm behind the globe.⁴ The OND and ONSD were similar in bilateral eyes in our study. This finding was also similar to a previous study.⁴

Diseases such as optic neuritis, optic nerve glioma, and neuromyelitis optica affect the optic nerve; whereas optic nerve sheath meningioma, and papilledema affect the optic nerve sheath complex. The value of the mean diameter of the optic nerve and optic nerve sheath could help in the differential diagnosis of these different diseases.

This study was conducted in a tertiary-level hospital in Nepal. We had a small sample size which was limited by the short study duration. Larger multicenter studies employing random sampling could be beneficial in the future. Measurement of the OND and especially the ONSD may be a useful

supplementary tool in the diagnosis of increased intracranial pressure.¹² Further research into determining cutoff values for ONSD diameters to diagnose increased intracranial pressure in patients undergoing MRI brain exams in the Nepalese population is recommended.

CONCLUSION

We measured the diameter of ON and ONS at two different levels. The measurements for the diameter of the optic nerve and optic nerve sheath complex were similar in both the right and left eyes. There was no significant difference in ON/ONS diameters between the two eyes, age, and gender of the participants.

ACKNOWLEDGEMENT

We thank our students/staff who helped us in data collection.

FINANCIAL SUPPORT

The author(s) did not receive any financial support for the research and/or publication of this article.

CONFLICT OF INTEREST

The author(s) declare that they do not have any conflicts of interest with respect to the research, authorship, and/or publication of this article.

REFERENCES

1. Smith AM, Czyn CN. Neuroanatomy, Cranial Nerve 2 (Optic).

- StatPearls [Internet]. 2022 Nov 7 [cited 2024 Apr 2]; Available from: <https://www.ncbi.nlm.nih.gov/books/NBK507907/>
- Mukherjee N, El-Dairi MA, Bhatti MT. Optic Nerve Sheath Fenestration—Indications and Techniques. *US Ophthalmic Rev.* 2013;06(02):125.
 - Mohamed IA, Ali HAW, Abati SMA, Alghamdi SS, Bushara L, Gareeballah A, et al. Radiographic Measurement of Normal Optic Nerve and Optic Nerve Sheath Diameters Using Different Modalities. Vol. 12, *International Journal of Biomedicine*. International Medical Research and Development Corporation; 2022. p. 349–54.
 - Watcharakorn A, Witayapiboon S, Mingkwansook V. Measurement of Normal Diameter of Optic Nerve and Optic Nerve Sheath Using MRI. 2021;
 - Vaiman M, Abuita R, Bekerman I. Optic nerve sheath diameters in healthy adults measured by computer tomography. *Int J Ophthalmol.* 2015;8(6):1240–4.
 - Gaddikeri S, Mossa-Basha M, Andre JB, Hippe DS, Anzai Y. Optimal Fat Suppression in Head and Neck MRI: Comparison of Multipoint Dixon with 2 Different Fat-Suppression Techniques, Spectral Presaturation and Inversion Recovery, and STIR. *Am J Neuroradiol.* 2018;39(2):362–8.
 - KC B, Thapa A. Study of Optic Nerve Sheath Diameter in Normal Nepalese Adults Using Ultrasound. *Birat J Heal Sci.* 2018;3(1):357–60.
 - Kim DH, Jun J-S, Kim R. Measurement of the Optic Nerve Sheath Diameter with Magnetic Resonance Imaging and Its Association with Eyeball Diameter in Healthy Adults. *J Clin Neurol [Internet].* 2018 Jul;14(3):345. Available from: <https://www.thejcn.com/DOIx.php?id=10.3988/jcn.2018.14.3.345>
 - Geeraerts T, Newcombe VFJ, Coles JP, Abate MG, Perkes IE, Hutchinson PJA, et al. Use of T2-weighted magnetic resonance imaging of the optic nerve sheath to detect raised intracranial pressure. *Crit Care.* 2008;12(5):1–7.
 - Peters R. Ageing and the brain. *Postgr Med J [Internet].* 2006 [cited 2024 Apr 4];82:84–8. Available from: www.postgradmedj.com
 - Avci M, Kozaci N, Komut E, Komut S, Caliskan G, Tubbas G. The Measurement of Elderly Volunteers' Optic Nerve Sheath Diameters by Ocular Ultrasonography. [cited 2024 Apr 4]; Available from: www.mdpi.com/journal/medicina
 - Shofty B, Ben-Sira L, Constantini S, Freedman S, Kesler A. Optic nerve sheath diameter on MR imaging: Establishment of norms and comparison of pediatric patients with idiopathic intracranial hypertension with healthy controls. *Am J Neuroradiol.* 2012;33(2):366–9.