

## Surgery for Solid Pseudopapillary Neoplasm: Observational Study at a Nepalese Tertiary Center

Dhruba N Sah<sup>1</sup>, Ramesh S Bhandari<sup>2</sup>, Prasan BS Kansakar<sup>3</sup>, Bikal Ghimire<sup>3</sup>, Paleswan Joshi Lakhey<sup>2</sup>

### Author(s) affiliation

<sup>1</sup>Department of General Surgery, Birat Medical College & Teaching Hospital

<sup>2</sup>Department of Surgical Gastroenterology, Maharajgunj Medical Campus, Tribhuvan University Teaching Hospital, Institute of Medicine, Maharajgunj, Kathmandu, Nepal

<sup>3</sup>Department of General Surgery, Maharajgunj Medical Campus, Tribhuvan University Teaching Hospital, Institute of Medicine, Maharajgunj, Kathmandu, Nepal

### Corresponding author

**Dhruba N Sah, MS, MCh**  
drshah\_dn@live.com  
ORCID iD - [0000-0001-6385-4466](https://orcid.org/0000-0001-6385-4466)

### Submitted

May 22, 2023

### Accepted

Oct 2, 2023

### ABSTRACT

#### Introduction

Solid pseudopapillary neoplasms (SPN) are rare, relatively indolent tumors with potential malignant behavior. This study aimed to analyze the clinicopathological details, surgical management, and short- and long-term outcomes of operated cases of SPN.

#### Methods

This was an observational descriptive study of diagnosed SPNs confirmed histopathologically after surgical resections at Tribhuvan University Teaching Hospital (TUTH), Kathmandu, Nepal from 2006 November to 2019 January. Patient's clinical details, surgical procedures, perioperative outcomes, and follow-up were recorded. Long-term follow-up was evaluated for a minimum of three years post-surgery.

#### Results

Over 13 years, a total of 15 cases with a median age of 22 years (11-52) were encountered and had female predominance (14, 93.3%). Five cases were diagnosed incidentally, while pain abdomen (5, 33.3%) was the most common presentation followed by lump (4, 26.7%). There were four tumors in the head of the pancreas, two in the uncinate process, two in the neck, four in the body, and three in the tail of the pancreas. Four cases underwent pancreaticoduodenectomy, three cases underwent enucleation, and four cases underwent central pancreatectomy. Similarly, one patient underwent spleen preserving distal pancreatectomy and three patients underwent distal pancretosplenectomy. Postoperatively, 20% developed major complications with Clavien-Dindo (grade III & above) out of which one patient had mortality. Over the median follow-up of 72 months, no recurrences were noted.

#### Conclusion

Solid pseudopapillary neoplasms were relatively rare. Complete surgical resection was the most commonly used surgical management, post-operative complications were minimal and survival rate was excellent.

#### Keywords

*Pancreas; solid pseudopapillary neoplasm; surgery*

## INTRODUCTION

Solid pseudopapillary neoplasm (SPN) was first reported by Frantz in 1959, as a rare pancreatic tumor with low malignant potential.<sup>1</sup> It consists of about 1-3% of all the pancreatic neoplasm and mostly occurs in young women.<sup>1</sup>

World Health Organization (WHO) 2010 classified SPN as an epithelial low-grade malignant neoplasm.<sup>2</sup> It is characterized by the sign of a well-circumscribed mass and a favorable prognosis after complete resection. SPN may present as nonspecific abdominal complaints, abdominal mass or fullness, and incidental radiological findings.<sup>3</sup> While the symptomatic presentation was prevalent in the past, the incidental finding is becoming more common now due to the widespread use of cross-sectional imaging.<sup>3</sup> Complete surgical resection is the main treatment of choice for SPN. The extent and type of surgery depend on the location of the tumor. Tumor located in the head of the pancreas may need pancreaticoduodenectomy (PD), that in the neck needs central resection and tumors in the body and tail are dealt with distal resection.<sup>3,4</sup> An aggressive surgical approach toward local and distal metastasis is justified due to excellent long-term prognosis even in the presence of metastatic disease.<sup>3</sup> Rarity of the occurrence of the disease and the sparse literature from our countries on this entity necessitates the need for conducting this study.

As Tribhuvan University Teaching Hospital (TUTH) is a tertiary referral center of Nepal performing pancreatic surgeries regularly, we evaluate the spectrum of SPN and its management along with short- and long-term follow-up at TUTH. This study aimed to evaluate the clinicopathologic features, operative details, and survival from 13 years of experience in a single center.

## METHODS

This was an observational descriptive study of operated cases of solid pseudopapillary neoplasm confirmed histopathologically at the Department of GI & General Surgery, TU Teaching Hospital, Kathmandu, Nepal between 2006 November and 2019 January. Long-term follow-up was assessed for patients with a minimum of 3 years post-surgery. Biopsies other than SPN were excluded. Data were collected from prospectively maintained data files from hospital records by the principal investigator and any discrepancies in details were confirmed with the respective surgeons of the cases. All demographics, preoperative, intraoperative, and postoperative records were noted. Surgeries had been performed as per the standard practice depending on the location of the tumor along with size and margin. All the perioperative events were graded as per Clavien-Dindo complications for

pancreatic surgery. Post-operative complications with Clavien-Dindo class  $\geq$ III and above were defined as major complications. Other procedure-specific complications like postoperative pancreatic fistula (POPF), post pancreatectomy hemorrhage (PPH), delayed gastric emptying (DGE), lymphatic fistula, etc were defined according to current International Study Group of Pancreatic Surgery (ISGPS) definitions. Follow-ups were assessed on an outpatient visit for 2 years and by telephone for the rest of the duration. Long-term follow-ups were recorded regarding symptom resolution, recurrence, and survival.

The study was approved by the Institutional Review Board, Institute of Medicine (IOM) TUTH (Reference Number - 256 (6-11) E2, 076/077). All data were analyzed using SPSS (version 20.0). Qualitative data were expressed in proportion and percentage, and quantitative data as mean  $\pm$  standard deviation or median (range).

## RESULTS

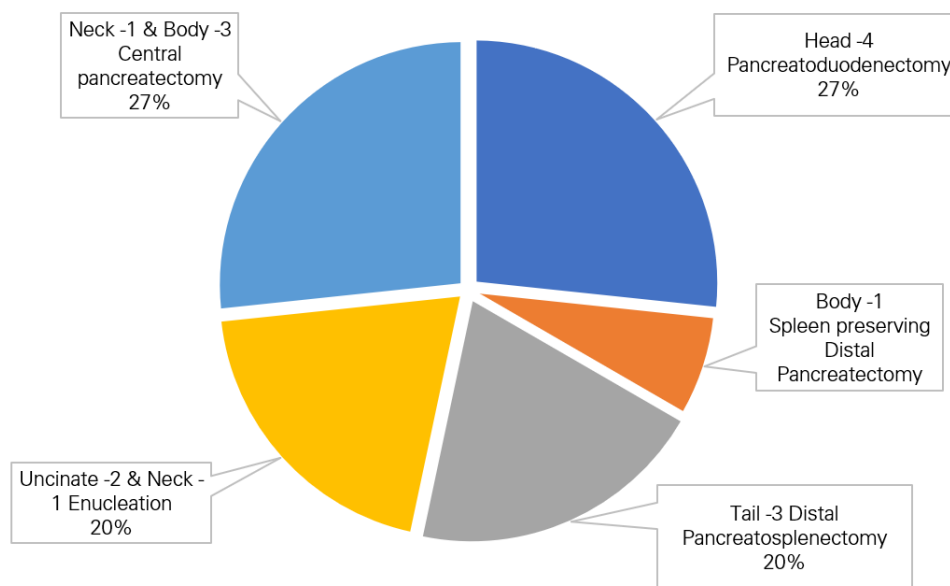
Over 13 years, a total of 15 cases of SPN were operated at our institution. Table 1 summarizes individual details of patients' characteristics along with clinical details, surgical procedures, perioperative outcomes, and follow-up data.

The mean age of the patients was  $24.87 \pm 9.9$  (range 11-52) with a female preponderance (93.3% female). One-third of patients were diagnosed with SPN incidentally on cross-sectional imaging done for other issues. Out of the remaining two-thirds, major presentations were pain abdomen (five, 33.3%) followed by lump (four, 26.7%) and jaundice in the remaining one patient. The median duration of symptoms was three months (range, 1-18 months) in symptomatic cases. Contrast-enhanced computerized tomography (CECT) was the main preoperative imaging tool in all the cases; additional magnetic resonance cholangiopancreatography (MRCP) or Endoscopic ultrasound (EUS) were not performed in any cases. Figure 1 describes various surgeries performed depending on the location and extent of the tumor.

Pancreaticoduodenectomy (PD) was performed in all four tumors involving the head of the pancreas out of which one patient underwent additional portal vein reconstruction (one cm of superior mesenteric vein resected & end-end anastomosis). Enucleation was performed in three cases (two cases located in the uncinate process and one in the neck of the pancreas). Central pancreatectomy (CP) was performed in four cases (one located at the neck while three located in the body region of the pancreas). Similarly, Spleen preserving distal pancreatectomy (DP) was performed in one case of the body pancreas while distal pancreatectomy (DPS) was performed in

**Table 1.** Details of patient characteristics, clinical details, surgical procedures, perioperative outcomes, and follow-up data of operated Solid pseudopapillary Neoplasm (n=15)

S.N	Year of Resection	Age (year)	Sex	Presentation	Location	Surgery	Tumor size max (cm)	Perioperative issues over 30 days	Hospital Stay (days)	Follow-up (months)	Follow-up Issues
1.	2006	18	F	Jaundice	Head	PD	7	IVA	16	150	No issues
2.	2008	23	F	Lump	Tail	DPS	10	No	5	146	No issues
3.	2009	52	F	Pain	Body	CP	7	V	9	NA	Expired at 9th POD
4.	2011	19	F	Incidental	Uncinate	Enucleation	4.5	I	6	124	No issues
5.	2012	35	F	Incidental	Uncinate	Enucleation	3	No	4	122	No issues
6.	2012	25	F	Incidental	Body	CP	6	II	10	110	No issues
7.	2014	27	F	Pain	Neck	CP	4	No	8	-	No issues
8.	2015	22	F	Lump	Tail	DPS	18	No	6	80	No issues
9.	2016	29	F	Pain	Body	DP	5	No	8	72	No issues
10.	2017	34	F	Pain	Neck	Enucleation	2.5	No	4	59	No issues
11.	2017	11	M	Lump	Head	PD	4	No	7	57	No issues
12.	2018	22	F	Lump	Head	PD	8	No	7	49	No issues
13.	2018	21	F	Pain	Head	PD	8	IIIA	15	48	Diabetes mellitus
14.	2018	15	F	Incidental	Tail	DPS	8	No	6	40	No issues
15.	2019	20	F	Incidental	Body	CP	3	I	6	38	No issues



**Figure 1.** Surgical procedures (15 cases of Solid Pseudopapillary Neoplasm) categorized location wise

three cases with tumors located at the tail of the pancreas. Operative photographs of different surgeries have been demonstrated in the following pictures (Figure 2-5).

The margin was negative (R0) in all cases with a median tumor size of six cm (range, 2.5-18 cm). None of the patients had lymph node metastasis (the range of lymph node retrieval was 0-16) & none had distant metastasis. Postoperatively, three (20%) patients developed major complications with Clavien-Dindo (grade III & above) out of which one (6.7%) patient had mortality. The patient who died was 55 years lady with SPN over the body of the pancreas, who underwent central pancreatectomy and developed a postoperative pancreatic fistula (POPF – grade C) with multiorgan dysfunction syndrome (MODS); expired on the ninth postoperative day. Two other cases with major complications were pancreaticoduodenectomies for SPN of the pancreatic head. The first case was of an 18-year-old female who had undergone PD and had grade B POPF in the intensive care unit (ICU) stay for four days for inotropic support with persistent drainage. The second case was of a 21-year-old female who had undergone PD and developed grade B POPF with extraluminal/ severe PPH that required embolization of pseudoaneurysm of the splenic artery. The median duration of hospital stay was seven days (range, 4-16) in patients who were discharged. The median duration of follow-up was 72 months (38–150 months). Long-term follow-up revealed no issues except the development of diabetes mellitus at 18 months follow-up (in a 22-year-old female who had PD). No recurrence was noted in any of the patients.

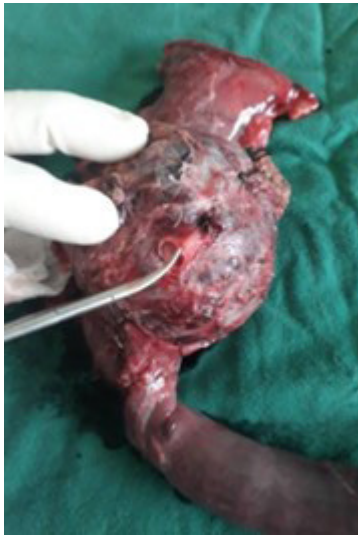## DISCUSSION

Solid pseudopapillary neoplasm is a rare pancreatic tumor with different biological behavior as compared to other pancreatic tumors. Following surgical resection, SPNs have an excellent prognosis with a reported five-year survival of more than 95%.<sup>5,6</sup>

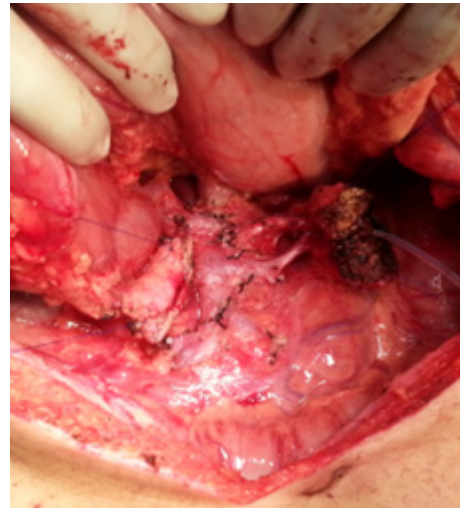The possibility of SPNs should always be considered in patients with pancreatic tumors in the younger age group. The mean age of patients was  $24.87 \pm 9.9$  years which is younger as compared to other reports of 31-37 years.<sup>7,8</sup> We had a female preponderance which is comparable to various published series,<sup>8</sup> however, the number of male patients has been increasing in recent times. Most of the patients are asymptomatic. One-third of the patients were diagnosed incidentally during regular abdominal scans which is similar to other published literature.<sup>6,8,9</sup> Contrary to other tumors of the pancreatic head, SPN rarely presents with jaundice.<sup>7</sup> We had only one case presented with jaundice out of four SPN of the head of the pancreas.

SPNs are usually indolent in course with low malignant potential. SPNs are localized tumors. Abdominal CECT has been the main diagnostic tool in this study with typical imaging findings of well-circumscribed, heterogeneously enhancing solid and cystic mass lesions. With atypical findings, MRI and/ or EUS with added fine needle aspiration (FNA) of lesions would help in differentiating from other pancreatic tumors. Usual tumor markers like CA19-9 and carcinoembryonic antigen (CEA) are usually normal. As the diagnosis is usually incidental, the size of tumors is larger (median 6 cm, range 2.5cm-18cm).

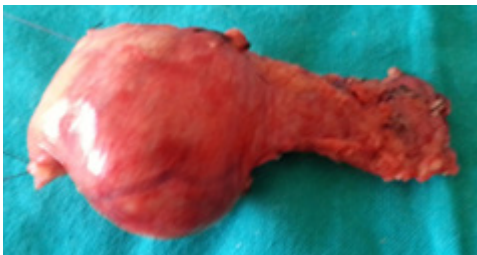Surgery is the only curative treatment modality because these well-circumscribed tumors usually



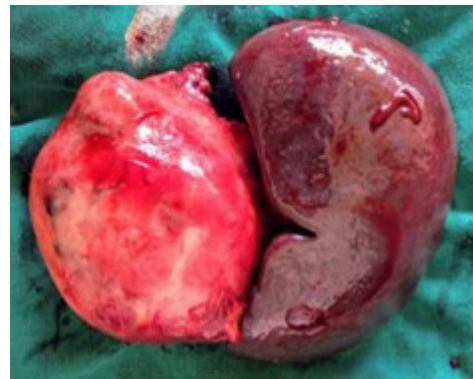**Figure 2.** 22-year lady with SPN over the head of the pancreas - underwent Pancreaticoduodenectomy with venous reconstruction



**Figure 4.** 25 years lady with a tumor over the body of her pancreas underwent Central Pancreatectomy



**Figure 3.** 29 years lady with tumor over the body of pancreas - underwent Spleen preserving Distal Pancreatectomy



**Figure 5.** 15 years girl with a tumor over the tail of the pancreas underwent Distal Pancreatospfenectomy

have an excellent prognosis.<sup>7,10</sup> Regarding the choice of surgical procedure, function-preserving surgery has also been advocated in recent times.<sup>11</sup> Parenchyma preserving surgery might result in comparable oncological outcomes with better long-term functional outcomes as compared to conventional surgeries, especially for small SPNs.<sup>11</sup> Some argue for an increased chance of margin positivity with an increased risk of recurrence following function-preserving surgery.<sup>5</sup> Various published reports have demonstrated excellent 10-year disease-free survival rates more than 95% following surgical resection.<sup>12,13</sup> We had one death following CP done for pancreatic body SPN in this series, and the case was operated on in 2009. However, with better perioperative care and improved surgical techniques, perioperative complications have decreased and the remaining 14 patients are doing well.

Complete surgical resection without formal lymphadenectomies is preferred even when distant metastases are present or with recurrent tumors.<sup>14</sup> Extensive lymphatic clearance is not necessary for surgeries performed for SPN, as lymph node metastasis is rare.<sup>15</sup> Adjuvant therapy is not indicated in SPNs with radical resection with a negative margin.<sup>16</sup> The follow-up should be regular and for a longer duration to detect any late recurrences or pancreatic insufficiencies. The development of new-onset diabetes mellitus has been evaluated as endocrine pancreatic insufficiency which has been seen in one patient in this study. However, no cases of exocrine pancreatic insufficiency (diarrhea and steatorrhea with the resolution with pancreatic enzyme supplementation) were seen in this study on long-term follow-up.<sup>17</sup>

This study has some limitations. This is an observational descriptive study of a rare tumor of

the pancreas. As the study population is small, comparative analysis between groups of patients or treatment couldn't be performed.

## CONCLUSION

Solid pseudopapillary neoplasms were relatively rare at our center. Pancreaticoduodenectomy and central pancreatectomy were the most commonly used surgical management. Post-operative complications were minimal and survival rate was excellent. Recurrence was not seen.

## AUTHOR CONTRIBUTIONS

Study concept and design: DNS, P.J.L. Data collection: DNS, P.J.L, RSB, PBSK, and BG. Analysis and interpretation of data: DNS. Drafting of the manuscript: DNS. All authors read and approved the final manuscript.

## FINANCIAL SUPPORT

The author(s) did not receive any financial support for the research and/or publication of this article.

## CONFLICT OF INTEREST

The author(s) declare that they do not have any conflicts of interest with respect to the research, authorship, and/or publication of this article.

## DATA AVAILABILITY

The datasets used and/or analyzed during the current study are available from the corresponding author upon reasonable request.

## REFERENCES

- Papavramidis T, Papavramidis S. Solid Pseudopapillary Tumors of the Pancreas: Review of 718 Patients Reported in English Literature. *J Am Coll Surg*. 2005 Jun;200(6):965–72. DOI
- Bosman FT, World Health Organization, International Agency for Research on Cancer, editors. WHO classification of tumours of the digestive system. 4th ed. Lyon: International Agency for Research on Cancer; 2010. 417 p. (World Health Organization classification of tumours). DOI
- de Castro SMM, Singhal D, Aronson DC, et al. Management of Solid-pseudopapillary Neoplasms of the Pancreas: a Comparison with Standard Pancreatic Neoplasms. *World J Surg*. 2007 May;31(5):1130–5. DOI
- Romics L, Oláh A, Belágyi T, et al. Solid pseudopapillary neoplasm of the pancreas—proposed algorithms for diagnosis and surgical treatment. *Langenbecks Arch Surg*. 2010 Aug;395(6):747–55. DOI
- Tjaden C, Hassenpflug M, Hinz U, et al. Outcome and prognosis after pancreatectomy in patients with solid pseudopapillary neoplasms. *Pancreatology*. 2019 Jul;19(5):699–709. DOI
- Kang CM, Choi SH, Kim SC, et al. Predicting Recurrence of Pancreatic Solid Pseudopapillary Tumors After Surgical Resection: A Multicenter Analysis in Korea. *Ann Surg*. 2014 Aug;260(2):348–55. DOI
- Liu M, Liu J, Hu Q, et al. Management of solid pseudopapillary neoplasms of pancreas: A single center experience of 243 consecutive patients. *Pancreatology*. 2019 Jul;19(5):681–5. DOI
- Wright MJ, Javed AA, Saunders T, et al. Surgical Resection of 78 Pancreatic Solid Pseudopapillary Tumors: a 30-Year Single Institutional Experience. *J Gastrointest Surg*. 2020 Apr;24(4):874–81. DOI
- Zhan H, Cheng Y, Wang L, et al. Clinicopathological Features and Treatment Outcomes of Solid Pseudopapillary Neoplasms of the Pancreas: A 10-Year Case Series from a Single Center. *J Laparosc Adv Surg Tech*. 2019 May;29(5):lap.2018.0704. DOI
- Cai Y, Ran X, Xie S, et al. Surgical Management and Long-Term Follow-Up of Solid Pseudopapillary Tumor of Pancreas: A Large Series from a Single Institution. *J Gastrointest Surg*. 2014 May;18(5):935–40. DOI
- Wang X, Chen YH, Tan C lu, et al. Enucleation of pancreatic solid pseudopapillary neoplasm: Short-term and long-term outcomes from a 7-year large single-center experience. *Eur J Surg Oncol*. 2018 May;44(5):644–50. DOI
- Huffman BM, Westin G, Alsidawi S, et al. Survival and Prognostic Factors in Patients With Solid Pseudopapillary Neoplasms of the Pancreas. *Pancreas*. 2018 Sep;47(8):1003–7. DOI
- Estrella JS, Li L, Rashid A, et al. Solid Pseudopapillary Neoplasm of the Pancreas: Clinicopathologic and Survival Analyses of 64 Cases From A Single Institution. *Am J Surg Pathol*. 2014 Feb;38(2):147–57. DOI
- Sanhueza CT, Huffman BM, Jin Z, et al. Solid Pseudopapillary Neoplasms of the Pancreas: A Large American Cohort. *Pancreas*. 2019 Apr;48(4):e21–2. DOI
- Lubezky N, Papoulas M, Lessing Y, et al. Solid pseudopapillary neoplasm of the pancreas: Management and long-term outcome. *Eur J Surg Oncol EJSO*. 2017 Jun;43(6):1056–60. DOI
- Din NU, Rahim S, Abdul-Ghafar J, et al. Clinicopathological and immunohistochemical study of 29 cases of solid-pseudopapillary neoplasms of the pancreas in patients under 20 years of age along with detailed review of literature. *Diagn Pathol*. 2020 Dec 9;15(1):139. DOI
- Kang JS, Jang JY, Kang MJ, et al. Endocrine Function Impairment After Distal Pancreatectomy: Incidence and Related Factors. *World J Surg*. 2016 Feb 1;40(2):440–6. DOI