

## Buccal Mucosal Graft Urethroplasty for Complex Urethral Strictures: A Single Center Study

Pawan R Chalise, Bhojraj Luitel, Suman Chapagain, Sujeet Poudyal, Manish M Pradhan, Purushottam Parajuli, Uttam K Sharma, Prem R Gyawali

### Author(s) affiliation

Department of Urology and  
Kidney Transplantation Surgery,  
Maharajgunj Medical Campus,  
Tribhuvan University Teaching  
Hospital, Institute of Medicine,  
Maharajgunj, Kathmandu, Nepal

### Corresponding author

**Pawan R Chalise, MS, MCh**  
pawan\_rc@yahoo.com

### Submitted

Feb 25, 2023

### Accepted

May 5, 2023

### ABSTRACT

#### Introduction

Urethral strictures have been a surgical challenge for the reconstruction urologists. Lichen sclerosus is the most common cause of urethral stricture in the developing world. There are different free graft tissues for urethroplasty but buccal mucosal graft (BMG) urethroplasty is an effective and versatile procedure for inflammatory and long segment urethral strictures.

#### Methods

A total of 64 cases who had complex urethral strictures underwent dorsal onlay BMG urethroplasty. BMG was harvested from cheeks or sublingual mucosa depending upon the length of the stricture. The catheter was removed after 3 weeks and patients were evaluated with uroflowmetry. The surgery was considered successful if subjective and objective parameters were satisfactory.

#### Results

Average length of the harvested graft was 14.5 cm (10-18 cm) in 42 panurethral, eight distal penile, four proximal penile and bulbar, and 10 bulbar urethral strictures. Postoperative period was uneventful except in four, of which two developed urethral fistulas and the other two developed periurethral abscess which resolved after treatment. After catheter removal, all voided with satisfaction. All patients, reassessed after mean period of 21 months, had satisfactory voiding. Two patients underwent visual internal urethrotomy for stricture at proximal site of BMG placement. There were no complications observed in the donor site with complete healing in all.

#### Conclusion

Dorsal onlay BMG Urethroplasty is an effective and versatile procedure for anterior urethral strictures with excellent results and with minimal donor site morbidity.

#### Keywords

*Buccal mucosal graft; Lichen sclerosus; panurethral; urethroplasty*

## INTRODUCTION

Reconstruction of urethra has been a challenging and competent procedure but is not without involvement. Blunt perineal trauma, instrumentation, ischemia due to indwelling catheter, infection (urethritis) and Lichen Sclerosus (LS) are the common causes of urethral stricture. Initially reserved for those strictures after which the instrumentation had become impossible, nowadays, primary urethroplasty is the procedure of choice for all urethral strictures.<sup>1</sup> Previously, urethral dilatation and visual internal urethrotomy (VIU) were the procedures of choice but repeated multiple procedures with high failure rate for this recurring disease made urethroplasty an ever evolving procedure.<sup>2</sup>

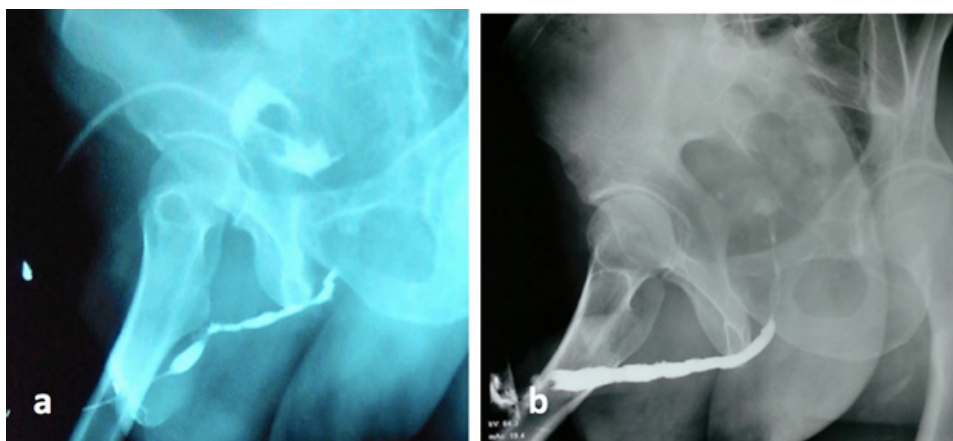
Development of better anaesthetic care, antibiotic treatment and surgical improvements have made this procedure safe and highly yielding. There are principally two types of surgical procedures— anastomotic urethroplasty for short (<2 cm) non-inflammatory strictures and substitution urethroplasty for long (>2 cm) or inflammatory strictures. A large variety of free graft tissues has been used for substitution urethroplasty, such as the full-thickness skin, ureter, saphenous vein, appendix, bladder mucosa and buccal mucosa.<sup>3</sup> However, buccal mucosa has stood the test of time. LS being the primary disease of the skin, the use of full-thickness has high recurrence.<sup>4</sup> Moreover, the beneficial characteristics of buccal mucosa like constant availability, easy harvesting, self-healing property of the donor site, favorable immunological properties, being moist, hairless and having tissue characteristics like thick epithelium, high content of elastic fibers, thin lamina propria and rich vascularization have made it the tissue of choice for urethroplasty.<sup>5</sup>

BMG has been used in various ways for reconstruction in the form of dorsal, ventral or dorsolateral onlay grafting for single stage urethroplasty or in two stage urethroplasty, all depending upon the caliber of stricture and the choice of surgeons.<sup>5-7</sup> We describe our short-term experience with buccal mucosal grafts, placed dorsally, for the treatment of long anterior urethral strictures.

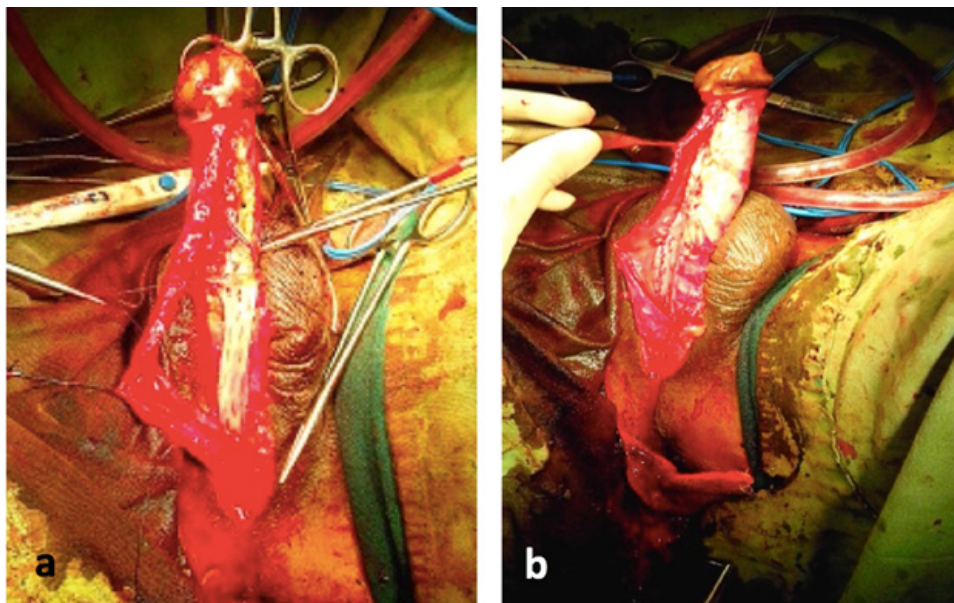
## METHODS

We prospectively studied a total of 64 cases who had long anterior urethral strictures and underwent urethroplasties from July 2013 to August 2020 in Tribhuvan University Teaching Hospital. All records were maintained in the form of proforma made prospectively. Dorsal onlay buccal mucosal graft urethroplasty was done for 42 panurethral and 22 isolated inflammatory anterior urethral strictures. All had undergone preoperative retrograde urethrography (RUG) and micturating cystourethrogram (MCUG) (Fig 1). Urine culture was negative in all patients before surgery.

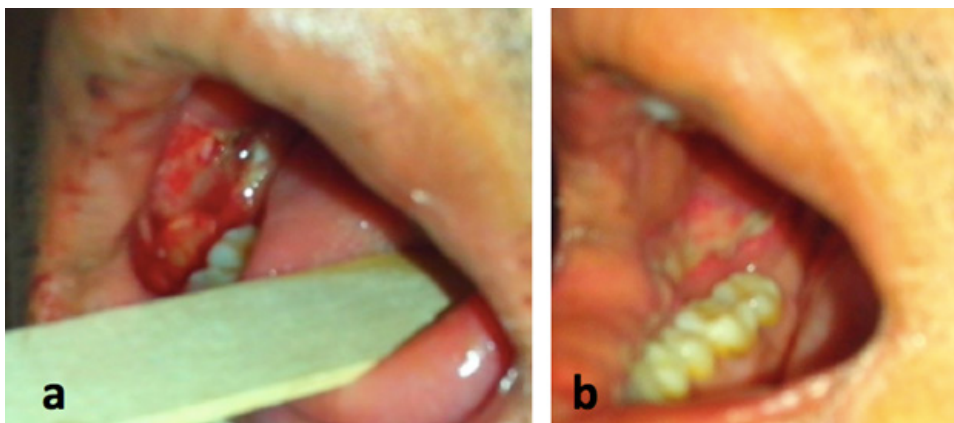
All urethroplasties were done under general anaesthesia with nasotracheal tube in lithotomy position. The case was planned for BMG urethroplasty only if urethra could be assessed with 6F pediatric cystoscope or ureterescope or 6F catheter could be negotiated. Urethra was approached through circumcoronal in all distal penile strictures, circumcoronal and midperineal or midperineal incision in all panurethral strictures whereas midperineal incision in all bulbar or proximal penile and bulbar strictures. Urethra was mobilized and longitudinal incision was given dorsally along the strictured segment reaching healthy urethra on either side of it. A 2 cm wide buccal mucosa with length as needed was harvested from unilateral or bilateral cheeks or sublingual area. The wound in



**Figure 1.** (a) Preoperative retrograde urethrography showing panurethral stricture, and (b) Postoperative film showing normal urethral lumen



**Figure 2.** Dorsal onlay buccal mucosal grafting after quilting (a) and suturing urethral edge with buccal mucosal graft margin and tunica albuginea (b)



**Figure 3.** Buccal mucosal grafting donor site on first post-operative day (a) and on fifth post-operative day (b)

buccal mucosa was sutured only when required. After defatting and piecrusting of the graft, it was applied over the tunica albuginea ventrally corresponding to diseased segment and quilted using Vicryl 6.0. Urethral edges were then sutured with Vicryl 6.0 continuously to the graft margins and tunica albuginea over 16 French silicone catheter (Fig 2). The catheter was removed after 3 weeks. Then the patient was assessed immediately with subjective symptoms.

Reassessment was done with subjective symptoms and uroflowmetry or retrograde urethrography or urethroscopy after 3 months and then after with subjective symptoms and uroflowmetry. The surgery was considered successful if subjective and one of the objective parameters were satisfactory.

## RESULTS

The age of patients ranged from 14 to 80 years

(median age-37 years). There were 42 panurethral, eight distal penile, four proximal penile and bulbar and 10 bulbar urethral strictures. All panurethral and eight distal penile strictures were due to Lichen Sclerosus whereas catheter-induced injury resulted in four bulbar and two proximal penile and bulbar urethral strictures and urethritis caused six bulbar and two proximal penile and bulbar urethral strictures. Six of bulbar urethral strictures had undergone Visual Internal Urethrotomy (VIU) before. Nine panurethral strictures had undergone meatoplasty of whom seven also had VIU and three had repeated urethral dilatation. Urethra was approached through circumcoronal incision in all distal penile strictures, circumcoronal and midperineal incision in 20 of the panurethral strictures whereas only midperineal incision in 22 panurethral strictures and all proximal penile and bulbar strictures. Average length of the harvested graft was 14.5 cm (10-18 cm) in panurethral, 4 cm

(3-6 cm) in distal penile and 3.7 cm (2-5 cm) in bulbar strictures and 7cm (5-8 cm) in proximal penile and bulbar urethral strictures. Graft was harvested from both cheeks in 40 cases, from one cheek in 20 cases and from both cheeks and sublingual mucosa in four. The donor site was sutured only in 18 cases.

Postoperative period was uneventful in all except in four, of which two developed urethral fistulas and the other two developed periurethral abscess. The urethral fistula needed repair whereas periurethral abscess resolved after drainage and antibiotics. In six patients, catheters were continued for 4 weeks due to complication like periurethral abscess and fistulas. After catheter removal, all voided with satisfaction. Mean duration of follow up was 21 months (range-3 to 40 months). All patients, except six, reassessed after 3 months had satisfactory voiding and uroflowmetry with peak average flow of 18 ml/s (12-31 ml/s). Among the six patient, four had meatal stenosis, which required meatal calibration and regular dilatation, and two had undergone meatoplasty. Two cases presented with stricture arising at the proximal part of BMG placement after six months and one year respectively and were managed with VIU. All other patients who got followed after one year had satisfactory voiding and uroflowmetry showing peak flow of average of 16 ml/s (11-26 ml/s).

On first postoperative day, all cases had mild pain and swelling of cheek which got gradually reduced on the following day. All tolerated liquid diet on the first postoperative day, soft diet the next day and resumed normal diet in next 1-2 days. The donor site healed completely by 5th post-operative days in all the cases. There were no complications observed in the donor site and no one complained of salivation disturbances, perioral numbness or difficulty in opening mouth.

## DISCUSSION

The ever-evolving techniques of urethroplasty have brought about a drastic change in the field of urethral strictures. Visual internal urethrotomy and urethral dilatation, though appealing both for urologists and patients as it is minimally invasive, recent studies with longer follow-up have shown a poor success rate ranging from 6% to 28%.<sup>8</sup> Significant number of patients in our study underwent VIU and dilatation without success. As we have started performing urethroplasty just few years back, most of the cases had undergone VIU and dilatation multiple times. Nowadays we advocate primary urethroplasty in almost all urethral strictures, reserving VIU for atmost one attempt in ring type of bulbar urethral strictures <1 cm. Short uncomplicated strictures are generally amenable to complete excision with primary anastomosis whereas longer strictures are managed using augmented roof anastomosis or

substitution onlay graft urethroplasty.<sup>9-13</sup>

In our region, Lichen Sclerosus (LS) is a major cause of panurethral strictures. Urethral involvement in LS can be seen in upto 30% cases and it varies from meatal stenosis to more extensive panurethral strictures. LS, being the primary disease of the skin, the use of full- thickness skin graft has high recurrence.<sup>4</sup> BMG was first described for urethral reconstruction by Humby in 1941 but resurgence in its application only took place in the late 1980s and early 1990s.<sup>14</sup> In 1998, Barbagli et al first reported 37 patients treated with dorsal onlay grafts, including 6 patients with BMG with 100 % success rate observed in BMG subset over 43 months. We have applied this Barbagli's novel technique of dorsal onlay urethroplasty in all our procedures and the result was excellent.<sup>15</sup> Similarly, Andrich and Mundy reported success of 95% in follow-up over 48-60 months in 71 patients who underwent 33 Barbagli procedures and 9 augmented roof strip procedures.<sup>16</sup> Pansadoro et al described a 98% success rate over median follow-up of 41 months in 56 patients who underwent dorsal onlay BM grafts.<sup>17</sup>

Kulkarni et al reported overall success of 83.5% in 117 men who underwent BMG urethroplasty for panurethral stricture.<sup>18</sup> All strictures were approached through single perineal incision. We also have used single perineal incision in 22 of our panurethral strictures and this avoided penile incision with preservation of penile cosmesis.

Though in our study, there were no problems related to donor site even on follow-up, it is not without complications. Barbagli et al has reported parotid duct damage, intraoperative bleeding, facial hematoma, infection, subjective local disturbances, neural damage, retraction from scar and limited mouth opening.<sup>19</sup> Stefan et al reported that BM graft harvesting from the lower lip resulted in a significantly greater long-term morbidity due to damage to mental nerve.<sup>20</sup> Dubey et al has reported bleeding from donor site which even required surgical intervention.<sup>21</sup>

Literatures have mentioned different positions (ventral or lateral onlay) for buccal mucosal graft placement, however, none have proved to be superior than the dorsal onlay.<sup>22-25</sup> The reason may be due to mechanical support provided by the corpora cavernosa, better blood supply and thus less prone to sacculation in dorsal onlay procedures.

This is our first single surgeon and institution based experience in dorsal onlay BMG urethroplasty in limited number of patients. At first, the patients were followed with urethroscopy or retrograde urethrogram along with uroflowmetry but currently avoiding invasive procedures and radiation, we routinely use patient's symptoms and uroflowmetry as outcomes of the intervention and move further

with other investigations when required. Due to short duration of follow up and Lichen Sclerosus being itself a recurring disease, no comments can be made on the long term results of urethroplasty from the current study.

## CONCLUSION

Dorsal onlay BMG Urethroplasty is an effective and versatile procedure for anterior urethral strictures with excellent results and with minimal donor site morbidity.

## FINANCIAL SUPPORT

The author(s) did not receive any financial support for the research and/or publication of this article.

## CONFLICT OF INTEREST

The author(s) declare that they do not have any conflicts of interest with respect to the research, authorship, and/or publication of this article.

## REFERENCES

- Rourke KF, Jordan GH. Primary urethral reconstruction: the cost minimized approach to the bulbous urethral stricture. *J Urol* 2005;173:1206–10.
- Greenwell TJ, Castle C, Andrich DE, MacDonald JT, Nicol DL, Mundy AR. Repeat urethrotomy and dilatation for the treatment of urethral stricture are neither clinically effective nor cost-effective. *J Urol* 2004;172:275–7.
- Dessanti A, Rigamonti W, Merulla V, Falchetti D, Caccia G. Autologous buccal mucosa graft for hypospadias repair: an initial report. *J Urol* 1992;147:1021–3.
- Alsifaki, NF, Arrendondo, SA and McAninch, JW. The efficacy of penile fasciocutaneous flaps in the treatment of urethral strictures caused by BXO. *J Urol* 2004;171(4S):18.
- Heinke T, Gerharz EW, Bonfig R, Riedmiller H. Ventral onlay urethroplasty using buccal mucosa for complex stricture repair. *Urology* 2003;61(5):1004-7.
- Patterson JM, Chapple CR. Surgical techniques in substitution urethroplasty using buccal mucosa for the treatment of anterior urethral strictures. *Eur Urol* 2008;53:1162-71.
- Palminteri E, Lazzeri M, Guazzoni G, Turini D, Barbagli G. New 2-stage buccal mucosal graft urethroplasty. *J Urol* 2002;167:130-2.
- Dubey D. The current role of direct vision internal urethrotomy and self-catheterization for anterior urethral strictures. *Indian J Urol* 2011;27:392-6.
- Peterson AC, Webster GD. Management of urethral stricture disease: developing options for surgical intervention. *BJU Int* 2004;94(7):971-6.
- Barbagli G, Palminteri E, Lazzeri M and Guazzoni G. Anterior urethral strictures. *BJU Int* 2003;92:497-505.
- Guralnick ML and Webster GD: The augmented anastomotic urethroplasty: indications and outcome in 29 patients. *J Urol* 2001;165:1496-501.
- Choudhary AK, Jha Nawal. Is anastomotic urethroplasty is really superior than BMG augmented dorsal onlay urethroplasty in terms of outcomes and patient satisfaction: Our 4-year experience. *Can Urol Assoc J* 2015;9:E22.
- Barbagli G, Lazzeri M, Palminteri A and Turini D. Lichen sclerosus of male genitalia involving anterior urethra. *Lancet* 1999;354:429.
- Humby G. A one-stage operation for hypospadias. *Br J Surg* 1941;29:84–92. .
- Barbagli G, Palminteri E, Rizzo M. Dorsal onlay graft urethroplasty using penile skin or buccal mucosa in adult bulbourethral strictures. *J Urol* 1998;160:1307–9.
- Andrich DE, Leach CJ, Mundy AR. The Barbagli procedure gives the best results for patch urethroplasty of the bulbar urethra. *BJU Int* 2001;88:385–9.
- Pansadoro V, Emiliozzi P, Gaffi M, Scarpone P, DePaula F, Pizzo M. Buccal mucosa urethroplasty in the treatment of bulbar urethral strictures. *Urology* 2003;61:1008–10.
- Kulkarni SB, Joshi PM, Venkatesan K. Management of Panurethral Stricture Disease in India. *J Urol* 2012;188:824-30.
- Barbagli G, De Stefani S. Reconstruction of the bulbar urethra using dorsal onlay buccal mucosa grafts: new concepts and surgical tricks. *Indian J Urol* 2006;22:113–7.
- Stefan K, Thomas K, Mahmoud O, Axel H, Maurice SM, Peter A. Donor site morbidity in buccal mucosal urethroplasty: lower lip or inner cheek. *BJU Int* 2005;96:619–23.
- Dubey D, Kumar A, Bansal P. Substitution urethroplasty for anterior urethral strictures, a critical appraisal of various techniques. *BJU Int* 2003;91:215–8.
- Barbagli G, Palminteri E, Guazzoni G, Montorsi F, Turini D, Lazzeri M. Bulbar urethroplasty using buccal mucosa grafts placed on the ventral, dorsal or lateral surface of the urethra: are results affected by the surgical technique? *J Urol* 2005;174:955–8.
- Heinke T, Gerharz EW, Bonfig R, Riedmiller H. Ventral onlay urethroplasty using buccal mucosa for complex stricture repair. *Urology* 2003;61:1004–7.
- Elliott SP, Metro MJ, McAninch JW. Long-term follow-up of the ventrally placed buccal mucosa onlay graft in bulbar urethral reconstruction. *J Urol* 2003;169:1754–7.
- Fichtner J, Filipas D, Fisch M, Hohenfellner R, Thuroff JW. Long-term outcome of ventral buccal mucosa onlay graft urethroplasty for urethral stricture repair. *Urology* 2004;64:648–50.